

Bruce Ramshaw, MD FACS

---

# Abdominal Wall Reconstruction

## Transversus Abdominus Release (TAR) Approach

**Pre-operative preparation:** During the pre-operative period, the patient is asked to optimize their health and emotional state in preparation for surgery. This may include weight loss, immunonutrition therapy, smoking cessation, medical optimization, exercise and/or addressing any emotional issues such as anxiety, Post-traumatic stress disorder, etc.

**Multi-modal pain management:** Consider pre- and peri-operative multi-modal pain management which may include pre-operative and post-operative course of Gabapentim, peri-operative NSAIDs, TAP block with long-acting local anesthetic, intraoperative local anesthetic block and/or other modalities to attempt maximal pain relief.

**Incision:** In most cases, an incision is made to excise a large amount of skin and soft tissue, resecting skin and abdominal wall back to healthy, well-vascularized tissue (Fig. 1).

This is commonly an elliptical vertical incision excising prior scars, but may be an elliptical transverse incision or a Fleur-de-Lis (inverted T) type of incision. Typically, the umbilicus is excised and discarded during the skin and scar excision. This should be discussed with the patient pre-operatively. Some people do not want their umbilicus removed.

Many patients will understand when it is explained that to get to healthier, well-vascularized tissue, it requires removal of the umbilicus. For those patients who still do not consent to umbilectomy, working around the



Bruce Ramshaw, MD FACS

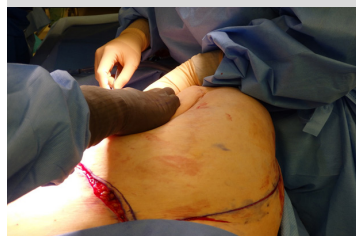

Figure 1: Wide excision of skin and soft tissue.

umbilicus, autotransplantation of the umbilicus or creation of a neoumbilicus by gathering skin and suturing down to the anterior fascia to create a dimple are options.

**Lysis of adhesions:** The resection of prior mesh and/or resection of wound sinus tract or enterocutaneous fistula are often required. Typically, all scar tissue, hernia sac, weakened fascia and foreign body (mesh, suture and any permanent fixation devices) are removed.

**Dissection:** The retrorectus space is entered medially between the posterior rectus sheath posteriorly and the rectus muscle anteriorly. The rectus muscle is dissected off of the posterior sheath to its lateral border. The posterior rectus sheath is incised very carefully just medial to the lateral border and just medial to the neurovascular bundles. This plane can be injected with long acting local anesthetic for an intraoperative plane block if desired (Fig. 2).

This injection can create a hydro-dissection plane making it easier to separate the transversus from the peritoneum (Fig. 3). This incision will divide the transversus abdominus and the preperitoneal space will be entered lateral to the rectus muscle. The transversus abdominus can then be separated from the peritoneum back to the level of the paraspinous muscles. This dissection is completed for the contralateral side to complete the bilateral myofascial advancement flaps maximizing the abdominal domain achieved and minimizing the tension on the midline closure. If loss of domain pre-

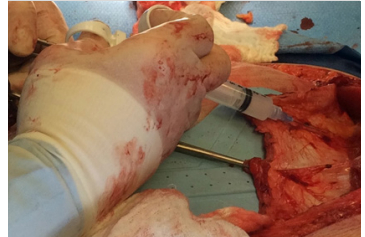


Figure 2: Injection of long-acting local anesthetic at neurovascular bundles on lateral border of posterior rectus sheath.

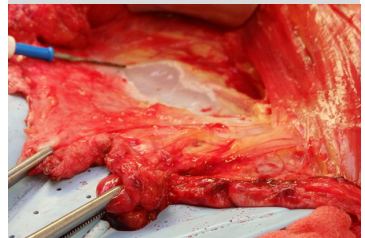


Figure 3: Hydro-dissection between transversus abdominus fascia and peritoneum to make dissection of this plane easier.

vents midline closure despite a complete bilateral release, visceral reduction should be considered to obtain full fascial closure (omentum, colon, etc.). The posterior fascia and peritoneum (below the arcuate line) is closed with a running long-term resorbable suture. Any holes in the peritoneum (not uncommon with the TAR approach) are closed if a macroporous mesh is used.

**Mesh placement:** A long term resorbable synthetic mesh is brought onto the field and fashioned to fit the size and shape of the field to achieve a retrorectus buttress. This will typically require a vertical length of up to 30 centimeters and horizontal length of up to 20 centimeters. The shape is usually elliptical.

**Mesh fixation:** A 0-Vicryl stitch is used to anchor the mesh at the midline inferiorly, often to the pubis. Then, interrupted sutures are placed bilaterally to the lateral cut transversus abdominus fascia maintaining the mesh taut as each suture is placed (Fig. 4). The final stitch is placed at the superior midline, often at the xiphoid process, to complete the mesh fixation (Fig. 5). If the mesh is adequately taut, the anterior fascial closure will not cause buckling or wrinkling of the mesh.

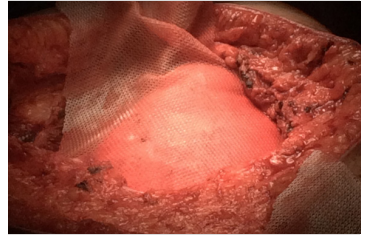


Figure 4: TIGR mesh implanted with interrupted sutures to cut lateral transversus abdominus fascia.

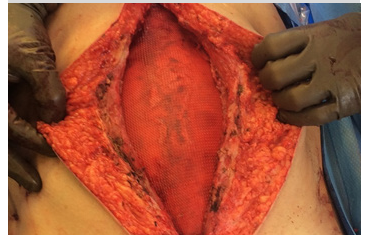


Figure 5: TIGR mesh completely implanted after TAR component separation.

**Closure:** After irrigation and addressing any bleeding, the anterior fascia is closed with a running long-term resorbable stitch. The subcutaneous tissue is irrigated and many quilting sutures are placed to eliminate dead space. For patients with a thick abdominal wall, the quilting sutures are done in 2-4 layers working the way up from the level of the fascia to the level of the skin (Fig. 6-9). This can prevent the need for drains and can decrease tension on the skin closure. The skin is closed with staples or a subcuticular running suture.

**Post-operative care:** The patient is usually sent to a regular floor room without abdominal drains; however a bladder catheter is often used overnight. Early ambulation, small amounts of liquids and small meals are encouraged within the first 24 hours. Prophylactic measures for deep vein thrombosis include sequential compression device, Lovenox® and early ambulation. Pulmonary measures include incentive spirometry and multi-modal pain management that results in less pain in most patients when walking, taking deep breaths and coughing. With this enhanced recovery program, many patients are able to be discharged by the third post-operative day.

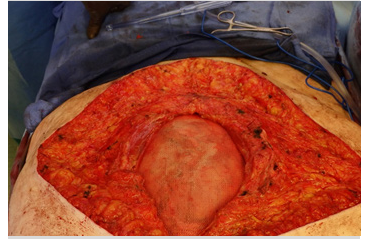


Figure 6: Another example of mesh placement prior to anterior fascia closure.

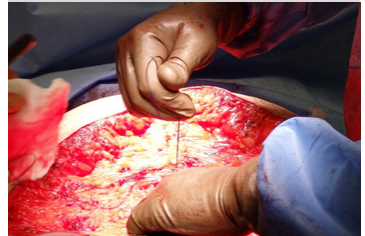

Figure 7: Closure of anterior fascia over the mesh.

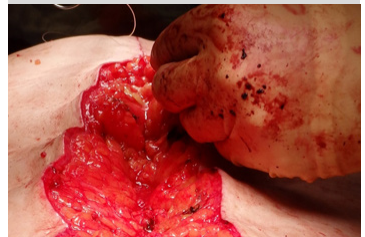


Figure 8: Closure of soft tissue in multiple layers with quilting sutures.

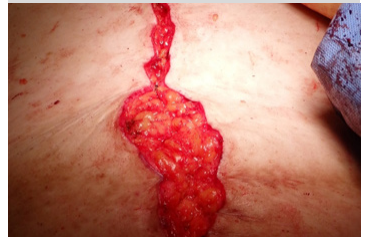

Figure 9: Continued layer closure of soft tissue and skin without the use of drains.

# Tips and tricks

1. Extensive resection of skin and scar tissue (including the umbilicus) and any non-healing wounds, ostomy sites, fistulas, etc. is recommended. This will allow approximation of healthy, vascularized tissue in the mid-line closure, eliminating the need for vascular identification technologies and minimizing wound complications. (Note: do let patients know that they will lose their umbilicus. If a patient does not want to have their umbilicus removed, sparing it in less complex AWR procedures is reasonable. For very complex AWR procedures, a neoumbilicus can be created by gathering a U-stitch of skin and fixing it to the midline fascia)
2. For severe loss of abdominal domain, we have found that visceral reduction can allow for complete midline closure: organs potentially resected include: omentum, small bowel (especially when involved in fistula, erosion into mesh and/or damaged from difficult lysis of adhesions) and colon.
3. Prior to performing the transversus abdominus release, injection of long-acting local anesthetic will potentially improve the effects of a TAP block and the infiltration of the liquid creates a plane that allows easier separation between the cut transversus abdominus and the peritoneum. We have experienced fewer tears in the peritoneum during this dissection after introducing this technique.
4. To ensure taut mesh placement, we have used 0-Vicryl® interrupted sutured to fix the long-term resorbable mesh in the retrorectus/preperitoneal space. Starting at the pubis, the mesh is then fixed laterally to the cut transversus abdominus fascia, which is retracted laterally. Sutures are placed back and forth from the right and left cut transversus abdominus fascia to distribute the tension equally. TIGR®Matrix mesh does stretch somewhat, so the bite of transversus abdominus fascia is taken 1-2 cm lateral and superior to where the lateral border of the mesh lies. This will allow a degree of tautness that prevents wrinkling of the mesh when the anterior fascia is closed.

# Tips and tricks

5. Many interrupted 2-0 and 3-0 Vicryl® sutures are used to approximate the subcutaneous tissue to achieve two goals: decrease the tension on the skin closure and eliminate dead space. The TAR technique with this approach to handling the subcutaneous tissue has allowed for the elimination of abdominal wall drains.
6. For some patients, especially those who have experienced traumatic episodes with staple removal and who are not at high risk for wound infection, a 4-0 subcuticular skin closure may be considered. This can be a significant issue in some patients from their perspective.
7. For patients who have undergone a prior component separation technique (CST) and have a recurrence, there are a few options: a repeat CST is possible, although instead of separating native musculofascia it will be scar tissue that developed from the prior operation that will be divided. A second option, especially if it is a small hernia, would be to offer a laparoscopic ventral hernia repair. In our experience, small hernias after a CST often occur at subxiphoid, suprapubic and/or lateral abdominal wall locations. Another option when additional AWR is indicated, is to use a TAR approach after a previous open or endoscopic CST (external oblique division). In these cases, a permanent mesh is used and sewn to the cut lateral transversus abdominus fascia in an attempt to minimize the risk of lateral bulging. We have utilized a non-woven polypropylene material for this purpose. In some cases, we have used the non-woven mesh alone and in some cases, we have sewn in the TIGR®Matrix mesh first because of the elasticity of the material and then sewn in the non-woven permanent synthetic mesh over the TIGR®Matrix. For cases that include the potential for exposed bowel, we have used microporous material (long-term resorbable Bio-A® or non-woven polypropylene mesh with a microporous silicone barrier to protect the viscera). In some cases, we have also sewn TIGR®Matrix over the microporous barrier if wider mesh coverage (without exposure to bowel) was appropriate.



Novus Scientific AB, Virdings allé 2, 754 50 Uppsala, Sweden  
Phone: +46 18 700 11 50 Fax: +46 18 700 11 51  
[info@novusscientific.com](mailto:info@novusscientific.com)



Surgical Momentum, Daytona Beach Office  
125 Basin Street, Suite 200, Daytona Beach, FL 32114  
Phone: (855) 900-4274  
[contact@surgicmomentuminc.com](mailto:contact@surgicmomentuminc.com)